

## GLENOID CAVITY MORPHOMETRY IN WESTERN RAJASTHAN: A STUDY OF ITS DIAMETERS AND INDEX

Mukesh Fulwaria<sup>1</sup>, Nand Lal<sup>2</sup>, Jaskaran Singh<sup>3</sup>, Kavita Pahuja<sup>4</sup>

<sup>1</sup>Senior Demonstrator, Department of Anatomy, Government medical college, Barmer, Rajasthan, India.

<sup>2</sup>Senior Professor, Department of anatomy, SMS medical college, Jaipur, Rajasthan, India.

<sup>3</sup>Associate Professor, Department of Anatomy, Govt Medical College, Jhunjhunu, Rajasthan, India

<sup>4</sup>Professor, Department of Anatomy, Sardar Patel Medical College, Bikaner, Rajasthan, India.

Received : 07/01/2025  
Received in revised form : 08/03/2025  
Accepted : 23/03/2025

**Keywords:**

Glenoid cavity, supero-inferior diameter, antero-posterior diameter, Glenoid Cavity Index (GCI), scapula morphology, orthopaedic surgery, Rajasthan population, anthropometry.

Corresponding Author:

**Dr. Kavita Pahuja,**

Email: kavita16pahuja@gmail.com

DOI: 10.47009/jamp.2025.7.2.67

Source of Support: Nil,

Conflict of Interest: None declared

*Int J Acad Med Pharm*  
2025; 7 (2); 331-334



### Abstract

**Background:** The morphology of the glenoid cavity, a critical component of the shoulder joint, has significant implications for orthopaedic surgery, anthropology, and biomechanics. **Materials and Method:** A total of 200 dry adult human scapulae were examined using standardized morphometric techniques in the western Rajasthan population. Supero-inferior (SI) diameter, antero-posterior (AP) diameters (AP-1 and AP-2) were measured with the help of Vernier calliper, and after then the Glenoid Cavity Index (GCI) was calculated. **Results:** Results showed mean SI diameters of  $36.63 \pm 3.32$  mm (right) and  $36.68 \pm 3.18$  mm (left), AP-1 diameters of  $25.14 \pm 2.88$  mm (right) and  $25.25 \pm 2.47$  mm (left), and AP-2 diameters of  $19.23 \pm 2.55$  mm (right) and  $18.98 \pm 2.23$  mm (left). The GCI values were  $68.61 \pm 4.60\%$  (right) and  $68.87 \pm 4.13\%$  (left), with no significant differences between sides ( $p > 0.05$ ). **Conclusion:** Comparisons with Indian and international studies revealed regional variations, likely influenced by genetic, environmental, and functional factors. These findings provide valuable insights for Orthopaedic procedures, prosthetic design, and anthropological research, emphasizing the importance of population-specific anatomical data.

## INTRODUCTION

The scapula, a key component of the shoulder girdle, plays a crucial role in upper limb mobility and stability. Among its anatomical features, the glenoid cavity is of particular importance due to its articulation with the humeral head, forming the gleno-humeral joint.<sup>[1]</sup> The morphology of the glenoid cavity, including its supero-inferior diameter, anteroposterior diameter, and glenoid cavity index (GCI), has significant implications for orthopedic surgery, anthropology, and biomechanics.<sup>[2,3]</sup> Understanding these dimensions is essential for improving clinical outcomes in procedures such as total shoulder arthroplasty, fracture fixation, and prosthesis design.<sup>[2]</sup> The supero-inferior diameter (SI diameter) of the glenoid cavity refers to the vertical measurement from its superior to inferior margins. This parameter is vital for assessing the overall size of the glenoid cavity and its capacity to accommodate the humeral head. Variations in SI diameter have been reported across different populations, suggesting genetic, environmental, and functional influences on scapular morphology.<sup>[4]</sup> Similarly, the anteroposterior diameter (AP diameter) of the glenoid cavity, measured along its transverse

axis, provides insight into the depth and stability of the glenohumeral joint. The AP diameter is further categorized into two specific dimensions: AP diameter 1, which represents the widest transverse measurement, and AP diameter 2, indicating the narrowest transverse dimension. These parameters are particularly relevant in determining the congruency and stability of the joint, influencing the risk of shoulder dislocation and the success of surgical interventions.<sup>[5]</sup>

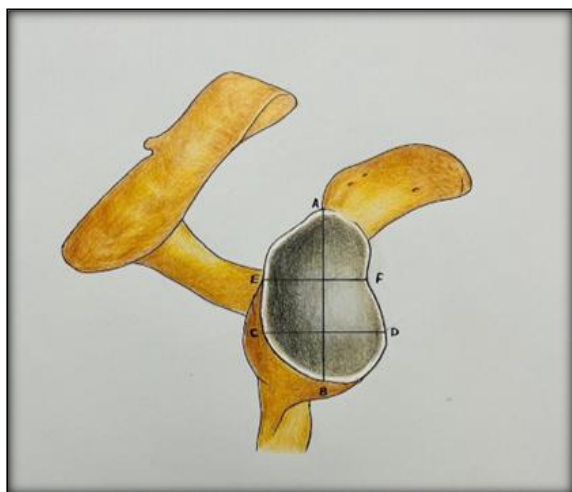
The glenoid cavity index (GCI), calculated as the ratio of the AP diameter to the SI diameter expressed as a percentage, serves as an important metric for assessing the shape of the glenoid cavity.<sup>[2]</sup> This index is crucial in anthropological studies to differentiate between population-specific variations and in clinical settings for optimizing prosthetic designs and surgical approaches.<sup>[3]</sup>

Given the clinical and anthropological significance of these parameters, the present study aims to analyze the supero-inferior diameter, antero-posterior diameter, and glenoid cavity index in western Rajasthan population. By comparing our findings with existing literature, present study seek to highlight regional variations and their potential

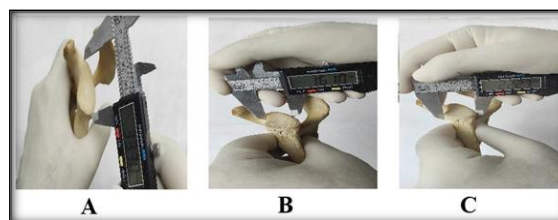
implications for orthopedic and reconstructive procedures.

## MATERIALS AND METHODS

The study was conducted on dry adult human scapulae collected from various medical colleges across Rajasthan. Ethical approval was granted by the Departmental Research Committee (DRC), Clinical Trial Screening Committee (CTSC), and the Institutional Ethical Committee (EC) S.M.S Medical college, Jaipur. The study utilized a descriptive observational design to analyze the morphological features of the scapulae. Inclusion criteria required intact, normal scapulae, while specimens with damage, fractures, or degenerative changes were excluded. Total 200 Scapulae were collected using convenience sampling. Data was collected using standardized anatomical and morphometric techniques, with three independent readings for each measurement to ensure accuracy. Tools like vernier calipers, linear metal scales, and a Nikon camera, were used for precise measurements. Key parameters measured included the superior-inferior (SI) diameter, antero-posterior diameters (AP-1 & AP-2), and the Glenoid Cavity Index (GCI) [Figure 1 & 2].

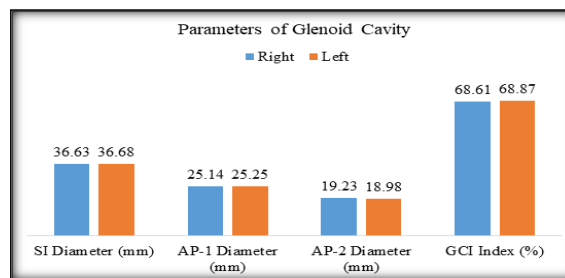


**Figure 1: Showing different dimensions of the glenoid cavity - AB: Superior-inferior diameter (SI), CD: Antero-posterior diameter-1 (AP-1), EF: Antero-posterior diameter-2 (AP-2).**



**Figure 2: Measurements of different dimensions of glenoid cavity- A: Superior-Inferior diameter (SI), B Anterior-Posterior diameter 2 (AP-2), C: Anterior-Posterior diameter 1 (AP-1).**

## RESULTS



**Figure 3: Diameters of glenoid cavity and glenoid cavity index**

[Table 1] presents the analysis of the glenoid cavity diameters and the Glenoid Cavity Index (GCI) for both the right and left sides. The mean superior-inferior (SI) diameter measured 36.63 mm on the right side and 36.68 mm on the left, with standard deviations of 3.32 mm and 3.18 mm, respectively. The mean antero-posterior diameter 1 (AP-1) was 25.14 mm on the right and 25.25 mm on the left, with standard deviations of 2.88 mm and 2.47 mm. The mean antero-posterior diameter 2 (AP-2) was 19.23 mm on the right and 18.98 mm on the left, with standard deviations of 2.55 mm and 2.23 mm, respectively. The GCI values were also similar, with mean values of 68.61 on the right and 68.87 on the left, and standard deviations of 4.60 and 4.13. The p-values for all parameters indicate no statistically significant differences between the right and left sides, suggesting symmetry in the glenoid cavity dimensions.

**Table 1: diameters of glenoid cavity and glenoid cavity index.**

Parameters	Side	Mean $\pm$ S.D.	P value
SI Diameter (mm)	Right Side	36.63 $\pm$ 3.32	0.917
	Left Side	36.68 $\pm$ 3.18	
AP-1 Diameter (mm)	Right Side	25.14 $\pm$ 2.88	0.782
	Left Side	25.25 $\pm$ 2.47	
AP-2 Diameter (mm)	Right Side	19.23 $\pm$ 2.55	0.473
	Left Side	18.98 $\pm$ 2.23	
GCI Index (%)	Right Side	68.61 $\pm$ 4.60	0.668
	Left Side	68.87 $\pm$ 4.13	

## DISCUSSION

The dimensions of the glenoid cavity are of great clinical significance, particularly in orthopedic and anthropological studies. Comparing the findings of Present study with previous literature provides valuable insights into regional variations, anatomical differences, and possible factors influencing the morphology of the glenoid cavity.

### **Superior-Inferior Diameter of the Glenoid Cavity**

The superior-inferior (SI) diameter of the glenoid cavity has shown a range of variations across different populations. Indian studies conducted by Mamatha et al. (2011) in Manipal, Rajput et al. (2012) in Gujarat, and Dhindsa & Singh (2014) in Punjab report SI diameters ranging from 33.67 mm to 34.76 mm.<sup>[6-8]</sup> Present study aligns closely with these findings, suggesting a similar trend in glenoid cavity morphology across different northern and western Indian populations.

However, studies conducted in South India, such as those by Philip et al. (2017) in Mysore and Parmar et al. (2019) in Bangalore, indicate slightly larger SI diameters (34.81 mm to 35.8 mm).<sup>[9,10]</sup> Similarly, studies from central and eastern regions, such as Bihar (Mahto, 2015; Akhtar et al., 2016), report even higher SI diameters, ranging from 35 mm to 36 mm, suggesting genetic or environmental influences on skeletal development.<sup>[11,12]</sup>

Comparatively, foreign studies report varying SI diameters. For example, Gamal et al. (2015) in Zagazig, Egypt, reported an SI diameter of 33.10 mm on the right side and 28.70 mm on the left side.<sup>[13]</sup> Ugwa et al. (2019) in Rivers State, Nigeria, found significantly higher values ( $40.55 \pm 2.61$  mm on the right and  $40.43 \pm 2.46$  mm on the left).<sup>[14]</sup> Similarly, Suroto et al. (2022) in Indonesia reported a mean SI diameter of  $37.6 \pm 2.1$  mm in males and  $32.6 \pm 2.6$  mm in females.<sup>[15]</sup> These variations suggest population-specific differences in scapular morphology.

### **Antero-Posterior Glenoid Diameter 1**

The antero-posterior glenoid diameter 1, representing the widest transverse dimension of the glenoid cavity, also exhibits variation across different studies. Our findings are in agreement with Indian studies conducted by Mamatha et al. (2011) and Rajput HB et al. (2012) where values range between 22.9 mm and 24.9 mm.<sup>[6,7]</sup>

Foreign studies show significant differences in this parameter. For instance, El din WA (2015) in Ismailia, Egypt, reported a mean AP glenoid diameter of  $21.33 \pm 2.49$  mm on the right and  $21.69 \pm 2.06$  mm on the left.<sup>[16]</sup> However, Zhou et al. (2022) in Japan found a larger AP diameter of  $27.13 \pm 1.70$  mm.<sup>[17]</sup> Similarly, Khan R (2019) in a South African population reported a mean value of  $18.4 \pm 3.3$  mm on the right and  $17.5 \pm 2.9$  mm on the left.<sup>[18]</sup> These variations could be attributed to genetic and lifestyle differences affecting bone morphology.

### **Antero-Posterior Glenoid Diameter 2**

The antero-posterior glenoid diameter 2, representing the narrowest transverse dimension, varies significantly across different studies. Present study findings closely match those reported by Gosavi S et al. (2014) in Pune with values around 15-16 mm.<sup>[19]</sup> Comparatively, foreign studies present notable differences. Ugwa et al. (2019) in Nigeria reported AP glenoid diameter 2 values of  $18.93 \pm 2.20$  mm on the right and  $18.52 \pm 1.73$  mm on the left.<sup>[14]</sup> Similarly, Alkesan et al. (2022) in Sohag, Egypt, found values of  $18.66 \pm 1.43$  mm on the right and  $18.15 \pm 1.61$  mm on the left.<sup>[20]</sup> In contrast, Suroto H et al. (2022) in Indonesia reported a mean AP diameter 2 of  $27.2 \pm 2.0$  mm in males and  $23.2 \pm 2.2$  mm in females, emphasizing the influence of sex-based differences.<sup>[15]</sup>

Several studies have explored asymmetry between the right and left glenoid cavities. The majority of Indian studies, including those by Dhindsa & Singh (2014) and Sarwar et al. (2015), indicate minimal differences between the two sides, with slightly larger values on the right side.<sup>[8,21]</sup> Present study also aligns with this trend, reinforcing the notion that the dominant side may exhibit marginally larger dimensions due to biomechanical adaptation over time. Foreign studies also report variations in side differences. Gamal et al. (2015) in Egypt found that the right SI diameter was significantly larger than the left (33.10 mm vs. 28.70 mm).<sup>[13]</sup> Similarly, Ugwa et al. (2019) in Nigeria and Alkesan et al. (2022) in Egypt observed slightly higher measurements on the right side.<sup>[14,20]</sup> However, El din WA (2015) in Egypt found minimal differences between the two sides.<sup>[16]</sup> When comparing the present study's findings with previous research, it is evident that the Glenoid Cavity Index (GCI) values in Rajasthan ( $68.61 \pm 4.60\%$  for the right and  $68.87 \pm 4.13\%$  for the left) align closely with several Indian studies, though some variations are observed. For instance, Dhindsa and Singh (2014) in Punjab reported a right GCI of  $70.37 \pm 4.36\%$  and a left GCI of  $68.59 \pm 4.08\%$ , showing a slightly higher value for the right side in their study, while the left side is nearly identical to the present study's findings.<sup>[8]</sup> Similarly, Chhabra, Prakash, and Mishra (2015) from Delhi recorded a right GCI of  $65.11 \pm 5.11\%$  and a left GCI of  $63.67 \pm 3.76\%$ , indicating lower values than those observed in the present study.<sup>[22]</sup> These differences could be attributed to factors such as regional anatomical variations, sample size, or the methodology employed in each study.

Other studies, like those by Akhtar et al. (2016) and Tiwari et al. (2018), report similar trends, with GCI values ranging between 63-71% in different regions of India.<sup>[12,23]</sup> Notably, studies like Kataria (2023) from Rajasthan reported much lower GCI values ( $16.13 \pm 2.48\%$  for the right and  $18.03 \pm 2.6\%$  for the left), which suggests a potential outlier or differing methodology, possibly focusing on a specific subgroup or population with distinct anatomical characteristics.<sup>[24]</sup> The consistent finding across

multiple studies, including the present one, points to a general trend of GCI values around 65-70% in the Indian population, though small regional differences are evident.

When considering foreign studies, the present study's GCI values are comparable to those found by Ugwa et al. (2019) in Nigeria, who reported  $65.83 \pm 4.94\%$  for the right and  $65.57 \pm 4.61\%$  for the left.<sup>[14]</sup> The GCI values in the present study are higher than those in Nigeria by about 2-3%, which could reflect differences in population genetics, diet, or lifestyle. The absence of data in several foreign studies, such as those from Egypt, South Africa, and Japan, limits direct comparisons, but the existing findings provide a valuable point of reference for understanding regional variations. Overall, the present study's GCI values appear consistent with Indian data, but regional and international comparisons highlight the need for further research to understand the underlying factors contributing to these differences.

## CONCLUSION

The comparison of Present study with previous Indian and foreign literature reveals significant regional and inter-individual variations in glenoid cavity morphology. While our findings align with many Indian studies, notable differences exist when compared with foreign populations. These differences may be attributed to genetic, environmental, and functional factors influencing skeletal development. Understanding these variations is crucial in orthopedic surgery, prosthetic design, and forensic anthropology. Future studies incorporating larger sample sizes and advanced imaging techniques may help establish a more comprehensive understanding of glenoid cavity dimensions across diverse populations.

## REFERENCES

1. Chang LR, Anand P, Varacallo MA. Anatomy, shoulder and upper limb, glenohumeral joint. InStatPearls [Internet] 2023 Aug 8. StatPearls Publishing.
2. Singh R. (2020). Surgical Anatomy of the Glenoid Cavity and Its Use in Shoulder Arthroplasty Among the North Indian Population. *Cureus*, 12(12), e11940.
3. Tankala, M., Senapati, S., Behera, S. S., & Shamal, S. (2023). The Glenoid Fossa's Morphometric Investigation and Its Clinical Implications. *Cureus*, 15(6), e39981.
4. Sahu, D., Joshi, M., Rathod, V., Nathani, P., Valavi, A. S., & Jagiasi, J. D. (2020). Geometric analysis of the humeral head

and glenoid in the Indian population and its clinical significance. *JSES international*, 4(4), 992-1001.

5. Zhou, J., Zhong, B., Qu, R., Qian, L., Li, Z., Liu, C., Xiao, Z., Xu, G., Liang, H., Wei, K., Ouyang, J., & Dai, J. (2022). Anatomic measurement of osseous parameters of the glenoid. *Scientific reports*, 12(1), 13424.
6. Mamatha H, Mamatha T, Suresh R, Bhagath KP. Morphometric study of glenoid cavity of dry human scapulae. *J Clin Diagn Res*. 2011;5(4):791-3.
7. Rajput HB, Vyas KK, Shroff BD. A study of morphological patterns of glenoid cavity of scapula. *Natl J Med Res*. 2012;2(4):504-7.
8. Dhindsa GS, Singh Z. Morphometric study of the glenoid cavity of dry scapulae in North Indian population. *J Clin Diagn Res*. 2014;8(7):AC07-10.
9. Philip SE, Prabavathy G, Boopalraj JM. Morphometric analysis of glenoid cavity in dry human scapulae. *Int J Anat Res*. 2017;5(3):4338-42.
10. Parmar T, Patel SV, Pensi CA. A study of glenoid cavity: Morphometry and its clinical implications. *J Clin Diagn Res*. 2019;13(1):AC01-4.
11. Mahto AK. Morphological and morphometrical study of glenoid cavity of human scapulae. *Int J Med Res Rev*. 2015;3(4):432-6.
12. Akhtar MJ, Yadav SK, Kumar A. Morphometric study of the glenoid cavity of scapulae in Bihar region. *Int J Anat Res*. 2016;4(3):2637-40.
13. Gamal AM, Kassem GM, Abul-Khair LA, Shamaa MA. Morphometric analysis of the glenoid cavity in adult Egyptian scapulae. *Zagazig Univ Med J*. 2015;21(3):108-15.
14. Ugwa OC, Nwachukwu CC, Okwudire EG, Ucheya RE. Glenoid cavity morphometry in adult Nigerian scapulae: A study on dry bones. *Int J Res Med Sci*. 2019;7(2):423-8.
15. Suroto H, Tamba ST, Widjajalaksmi AD. Morphometric variations of glenoid cavity among Indonesian populations. *J Anat Soc India*. 2022;71(4):211-6.
16. El din WA. Morphometric study of the glenoid cavity of scapulae in adult Egyptian population. *Egypt J Anat*. 2015;38(2):232-8.
17. Jing Z, Takahashi K, Nakatani T. Glenoid cavity dimensions in Japanese population: A morphometric study. *J Morphol*. 2022;283(2):115-21.
18. Khan R. Anatomical variations of the glenoid cavity among South African populations. *SA J Anat*. 2019;30(1):57-63.
19. Gosavi S, Jadhav SD, Zambre BR. Morphometric analysis of glenoid cavity of dry scapulae in Maharashtra population. *Int J Anat Res*. 2014;2(2):437-40.
20. Alkesan M, El-Shahat S, El-Kholy W. Glenoid cavity morphometry: A comparative study among Egyptian population. *Sohag Med J*. 2022;26(1):23-9.
21. Sarwar S, Hassan R, Alam M. Side differences in glenoid cavity dimensions: A comparative study. *Int J Anat Res*. 2015;3(1):532-7.
22. Chhabra S, Prakash M, Mishra BK. Study of glenoid cavity index in North Indian population. *Int J Anat Res*. 2015;3(4):1625-9.
23. Tiwari P, Sharma S, Kumar S. Evaluation of glenoid cavity index in different Indian populations. *J Anat Soc India*. 2018;67(2):123-8.
24. Kataria R. Morphometric analysis of glenoid cavity in Rajasthan population. *J Med Sci Clin Res*. 2023;11(6):45-50.